

12

AUTOPSY REPORT

No. 2023-14789

Perry, Matthew Langford

I performed an autopsy on the body of →

at _____ the DEPARTMENT OF MEDICAL EXAMINER

Los Angeles, California on 10/29/2023 0930
(Date) (Time)

From the anatomic findings and pertinent history I ascribe the death to:

(A) Acute effects of ketamine

DUE TO OR AS A CONSEQUENCE OF
(B)

DUE TO OR AS A CONSEQUENCE OF
(C)

DUE TO OR AS A CONSEQUENCE OF
(D)

OTHER CONDITIONS CONTRIBUTING BUT NOT RELATED TO THE IMMEDIATE CAUSE OF DEATH

Drowning; coronary artery disease; buprenorphine effects

MANNER OF DEATH

Accident

HOW INJURY OCCURRED

Unknown route of drug intake; found in residential pool

Anatomic Summary :

I. 54-year-old male with history of chronic obstructive pulmonary disease/emphysema, diabetes; drug use in past—reportedly clean for 19 months; heavy tobacco user for many years but currently not smoking; on ketamine infusion therapy with most recent therapy reportedly one and a half weeks before death

A. Found unresponsive floating face down in heated end of pool

B. Prescription medications and loose pills present at residence, however none reported near pool and no medications, drugs or drug paraphernalia adjacent to the pool

C. No signs of fatal trauma and no foul play suspected

II. Autopsy findings:

A. Focal, moderately severe left anterior descending coronary artery atherosclerosis with proximal to mid portions ranging from 50% to 75% narrowing; no thrombi are noted and there are no acute myocardial infarctions grossly identified

-Mild cardiomegaly, 465-gram heart with early left ventricular dilation

E. Lungs with marked anthracosis and bullous changes, as well as pulmonary edema and congestion

F. Nephrosclerosis of kidneys

G. Pancreatic fibrosis, chronic

12**AUTOPSY REPORT**

No. 2023-14789

Perry, Matthew

Page 2

- H. Remote abdominal surgery with chronic fibrous adhesions of intestines; mostly fluid contents in stomach
- I. Moderately severe aortic atherosclerosis
- J. Chronic hepatic congestion, liver; mild splenomegaly
- K. See separate microscopic, toxicology, microbiology reports

CIRCUMSTANCES :

Please see Medical Examiner Investigator's Report.

EXTERNAL EXAMINATION:

The body is identified by toe tags and is that of an unembalmed refrigerated adult male who appears the reported age of 54 years. The body measures 70 inches, weighs 216 pounds, and is normally developed, mildly obese with a body mass index (BMI) of 31.0. The nutritional status otherwise is unremarkable. Examination of the skin shows no evidence of jaundice. Mild immersion wrinkling of the hands and feet is noted. Early clubbing changes of nailbeds are noted. Yellowing of the right index nail is seen. Scars: Several abdominal scars, a back scar, non-linear bilateral forearm scars are noted. Tattoos: Not identified.

Rigor mortis is moderate. Livor mortis is blanching and posterior.

The head is normal in size and shape. The scalp hair is gray-brown. There is no temporal or vertex balding. Mustache is present, short goatee, with facial stubble. Full beard is absent. Examination of the eyes reveals irides that appear to be blue and sclerae that are congested. Transparent lens membrane of the right eye covers the iris. The conjunctivae are mildly congested. The oronasal passages are unobstructed. There is no foam in the nostrils or oral cavity. Upper and lower teeth are present with excellent dentition. Frenulae and oral mucosa are intact.

There is no chest deformity. There is mildly to moderately increased anterior-posterior diameter of the chest. The abdomen is mildly obese, status post remote surgery. The genitalia are

12**AUTOPSY REPORT**

No. 2023-14789

Perry, Matthew

Page 3

those of an adult male. The external genitalia are without trauma or lesions.

EVIDENCE OF THERAPEUTIC INTERVENTION:

There is no evidence of recent therapeutic intervention. Recent, distinct needle punctures are not identified. There has not been postmortem intervention for organ procurement.

POSTMORTEM CHANGES:

There is evidence of postmortem changes consisting of ant activity with abrasions appearing red-brown on the face due to discovery with prone face positioning, and yellow brown on hips, thighs and upper extremities. Tardieu spots present in a few areas of back.

EVIDENCE OF INJURY:

There is no evidence of fatal injury. There are sparsely scattered contusions of various ages with colorations including green, yellow, brown, and various extents of fading, as diagrammed.

INITIAL INCISION:

The body cavities are entered through the standard coronal incision and the standard Y-shaped incision. No foreign material is present in the mouth, upper airway, and trachea.

NECK:

The neck organs are removed en bloc with the tongue. There is no edema of the larynx. No foreign body obstructions are noted. Both hyoid bone and larynx are intact and without fractures. No hemorrhage is present in the adjacent throat organs investing fascia, strap muscles, thyroid, or visceral fascia. There are no prevertebral fascial hemorrhages. The tongue when sectioned shows no trauma.

CHEST/ABDOMINAL CAVITY:

Pleural effusions are present, about 50cc bilaterally. Pleural fibrous adhesions are sparse, chronic fibrous. The parietal pleurae are intact. Soft tissues of the thoracic and abdominal walls are well-preserved. The organs of the abdominal cavity have a normal arrangement, extensive chronic fibrous adhesions and other remote surgical changes are seen, and appendix is not

12**AUTOPSY REPORT**

No. 2023-14789

Perry, Matthew

Page 4

identified. Ascites is not present. The peritoneal cavity is without evidence of peritonitis.

SYSTEMIC AND ORGAN REVIEW:

Note: The following observations are limited to findings other than injuries, if described above.

MUSCULOSKELETAL SYSTEM:

No abnormalities of the uninjured bony framework or muscles are identified other than mild to moderate osteophytic spine changes.

CARDIOVASCULAR SYSTEM:

The thoracic aorta has mild and abdominal aorta has moderately severe atherosclerosis with calcification of plaque. There is no tortuosity or widening of the thoracic segment. There is no dilation of the lower abdominal segment. No aneurysm is present. The major branches of the aorta show no severe atherosclerotic abnormality. Within the pericardial sac there is serous fluid.

The heart weighs 465 grams. It has a normal configuration. The cardiac silhouette is slightly globular and the myocardium is not significantly flabby. The right ventricle is 0.5 cm, the interventricular septum is 1.5 cm in thickness, and the left ventricle is 1.5 cm in thickness. The chamber of the left ventricle shows early dilation and is without organized mural thrombosis. The valves are mostly thin, leafy, and competent, with minimal myxoid degeneration of the mitral. No cardiac valve vegetations are present. There is focal left ventricular endocardial fibrosis. There is no abnormality of the apices of the papillary musculature. There are no defects of the septum. The great vessels enter and leave in a normal fashion. The ductus arteriosus cannot be probed. The coronary ostia are patent, located at or below the sinotubular junction and are relatively centrally located within their respective sinuses. The coronary artery distribution is right dominant. Serial

12**AUTOPSY REPORT**

No. 2023-14789

Perry, Matthew

Page 5

sectioning of the left coronary artery shows 50% atherosclerosis just after the circumflex take-off, 65% narrowing about one centimeter past that, and 75% narrowing another centimeter down.

Circumflex and right coronary arteries have less than 25% narrowing.

RESPIRATORY SYSTEM:

Scant secretions are found in the upper respiratory and lower bronchial passages. The mucosa is intact. The right lung weighs 700 grams and the left lung weighs 690 grams. The pulmonary parenchyma is dark red-purple and the cut surfaces exude a moderate amount of blood and frothy fluid, with the more apical areas showing mild to moderate bullous changes. The visceral pleurae are dark with heavy anthracosis. The pulmonary vasculature is without thromboembolism. There is no evidence of pulmonary infarction.

GASTROINTESTINAL SYSTEM:

The esophagus is intact throughout. Esophageal varices are not present. The stomach contains approximately 40 cc of tan fluid with sparse non-specific food material. The mucosa is unremarkable for ulcerations. The small intestine and colon are unremarkable other than chronic serosal adhesions. The appendix is not identified. The pancreas occupies a normal position. There is no necrosis or trauma. There is evidence of relatively severe pancreatic fibrosis with focal calcification.

HEPATOBIILIARY SYSTEM:

The liver weighs 2020 grams, and is red-brown to light tan with so-called "nutmeg" appearance. The capsule is intact and the consistency of the parenchyma is soft. The cut surface is smooth. There is no evidence of cirrhosis. There is a normal lobular arrangement. The gallbladder is present. The wall is thin and pliable. It contains a moderate amount of bile and no calculi.

URINARY SYSTEM:

The right kidney weighs 185 grams and the left kidney weighs 200 grams. The kidneys are normally situated and the capsules strip easily revealing a surface that is pitted and focally scarred. The corticomedullary demarcation is preserved. The pyramids are

12**AUTOPSY REPORT**

No. 2023-14789

Perry, Matthew

Page 6

not remarkable. The peripelvic fat is somewhat increased. The ureters are without dilation or obstruction and pursue their normal course. The urinary bladder is unremarkable. It contains approximately 15 cc of hazy, yellow urine. The urine preliminary screen at autopsy is negative for ketones, glucose and negative for drugs on the screening cards, except inconclusive for benzodiazepines.

GENITAL SYSTEM:

The prostate is not enlarged and is without nodularity. Both testes are in the scrotum and are without trauma or focal lesions.

HEMOLYMPHATIC SYSTEM:

The spleen weighs 340 grams. The capsule is intact. The parenchyma is dark red and soft. There is no increased follicular pattern. The bone is not remarkable. The bone marrow of the rib is unremarkable.

ENDOCRINE SYSTEM:

The thyroid, adrenal, and pituitary glands are unremarkable. The parathyroid glands are not identified. The thymus is the usual appearance for the age.

SPECIAL SENSES:

The eyes are not dissected. The middle and inner ear are not dissected.

HEAD AND CENTRAL NERVOUS SYSTEM:

There is no subcutaneous, subgaleal, or subperiosteal hemorrhage in the scalp. The external periosteum and dura mater are stripped showing no fractures of the calvarium or base of the skull. Mild petrous congestion is noted. There are no tears of the dura mater. There is no epidural, subdural or subarachnoid hemorrhage.

The brain weighs 1450 grams. The leptomeninges are thin and transparent. A normal convolutionary pattern is observed. Coronal sectioning demonstrates a uniformity of cortical gray thickness. The basal ganglia are intact. Anatomic landmarks are preserved. Cerebral contusions are not present. The ventricular system has a normal appearance without dilation or

12**AUTOPSY REPORT**

No. 2023-14789

Perry, Matthew

Page 7

distortion. Pons, medulla, and cerebellum are unremarkable. There is no evidence of uncal or cerebellar herniation. Vessels at the base of the brain have a normal pattern of distribution. There are no aneurysms. The cerebral arteries are without significant arteriosclerosis.

SPINAL CORD:

The cervical spinal cord is examined through the foramen magnum and is grossly unremarkable.

EVIDENCE COLLECTION:

No physical evidence collected at autopsy.

HISTOLOGIC SECTIONS:

Representative sections from various organs are preserved in one storage jar.

HISTOLOGIC KEY:

- 1 - lungs
- 2 - lungs
- 3 - lungs
- 4 - kidney, liver
- 5 - heart

TOXICOLOGY:

Samples of heart blood, femoral blood, gastric contents, liver, bile, urine and vitreous are submitted to the laboratory. An EDTA tube is collected for blood typing.

SPECIAL PROCEDURES:

Nasopharyngeal swab for respiratory viral testing.

PHOTOGRAPHY:

Photographs have been taken prior to and during the course of the autopsy.

RADIOLOGY:

CT radiologic examination performed, no fractures or unusual radiodensities are seen.

12**AUTOPSY REPORT**

No. 2023-14789

Perry, Matthew

Page 8**WITNESSES:**

There were LAPD witnesses present during the autopsy.

DIAGRAMS USED:

Diagram forms #20, 21, and 22 were used during the performance of the autopsy. Coroner diagrams are not intended to be facsimiles nor are they drawn to scale.

SUMMARY & OPINION:

Mr. Matthew Perry's cause of death is determined to be from the acute effects of ketamine. Contributory factors in his death include drowning, coronary artery disease and buprenorphine effects. The manner of death is accident (drug and drowning related). No signs of foul play are suspected in this death. At the high levels of ketamine found in his postmortem blood specimens, the main lethal effects would be from both cardiovascular overstimulation and respiratory depression. Drowning contributes due to the likelihood of submersion into the pool as he lapsed into unconsciousness; coronary artery disease contributes due to exacerbation of ketamine induced myocardial effects on the heart. Buprenorphine effects are listed as contributory, even though not at toxic levels, due to the additive respiratory effects when present with high levels of ketamine.

Autopsy shows no fatal blunt or penetrating trauma. Coronary atherosclerotic disease is focally moderate, with a single vessel showing 50-75 percent narrowing. The heart is mildly enlarged. Lungs show emphysematous changes, edema and congestion. There is no sign of acute respiratory infections either by microbiology testing or microscopic examination.

Toxicology testing reveals ketamine levels at 3540 ng/ml (3.54 microgram/ml or mg/L) in a peripheral blood source, and 3271 ng/ml (3.27 microgram/ml or mg/L) in a central blood source in Mr. Perry's system. For context, in monitored surgical-anesthesiologic care, levels for general anesthesia are typically in the 1000-6000 ng/ml ranges. Also detected was buprenorphine, an opioid-like drug used in the treatment of opioid addiction as well as acute and chronic pain. The levels were therapeutic for the drug as well as its metabolite

12**AUTOPSY REPORT**

No. 2023-14789


Perry, Matthew

Page 9

norbuprenorphine, 8.0 and 17 ng/ml, respectively. Non-toxic levels of the benzodiazepine lorazepam were detected. Also, the metabolite of clonazepam, 7-aminoclonazepam, was detected. Clonazepam, however, was not detected. Alcohol, methamphetamine, cocaine, heroin, PCP, fentanyl were all not detected (negative).

Ketamine is a dissociative anesthetic with established human medical and surgical uses. Also, it is used in recreational drug use and other illicit settings, mainly due to its "dissociative" nature, indicating disconnection of mind from body. It also can have short duration hallucinatory and psychedelic effects. This latter effect explains its use in nightclub/party/rave culture.

The exact method of intake in Mr. Perry's case is unknown. There were trace amounts of ketamine detected in the stomach contents. He was reported to be receiving ketamine infusion therapy for depression and anxiety. Per the Medical Examiner Investigator's report, his last known treatment was 1 ½ weeks prior to death, and the ketamine in his system at death could not be from that infusion therapy, since ketamine's half-life is 3 to 4 hours, or less.


Raffi Djabourian, M.D.
Senior Deputy Medical Examiner

12/14/2023
Date

20

Decedent: PERRY, MATTHEW LANGFORD

Case Number: 2023-14789

-pbl
-mod rigor

See folio 22

4" gray-brn, w/lystrit, bald

blue, & patch, & citrus
stt cong sclera

No lesions

own teeth, excellent dentition

No trauma

scars 4 x 1/2"

Tardieu

25 scars
incl. old
surgical

1/2" 3 1/2" linear
9 x 3/4" vertical
surg.

distal hip
remot
amp.

gray sluff
about
facial stubble
1" postmort
skin
slip

No long
tracks

faded
purp-brn
ecchy
No shaft
linear
scars

circ

2 1/2 x 1" & 1 1/2 x 1"
11/2" scars

No lesions
or trauma

(B)
faint
illig
small
faded
scars

purp cont ecchy
1 1/2 x 3/16

4 x 1 1/2" purp
cont ecchy

No lesions

possible
dimpled scar
- No significant
nodules

postmort
ant activity
abcs

1" / 16" scars

23-14789

faded
old
5 1/2 x 4"
green-blue
cont ecchy

⊘ = not
present

ME x 2 (Perry)

0930 - 1215
Ext. / 2 strng / 1 cassette
NP
C / 14 tes / subserne

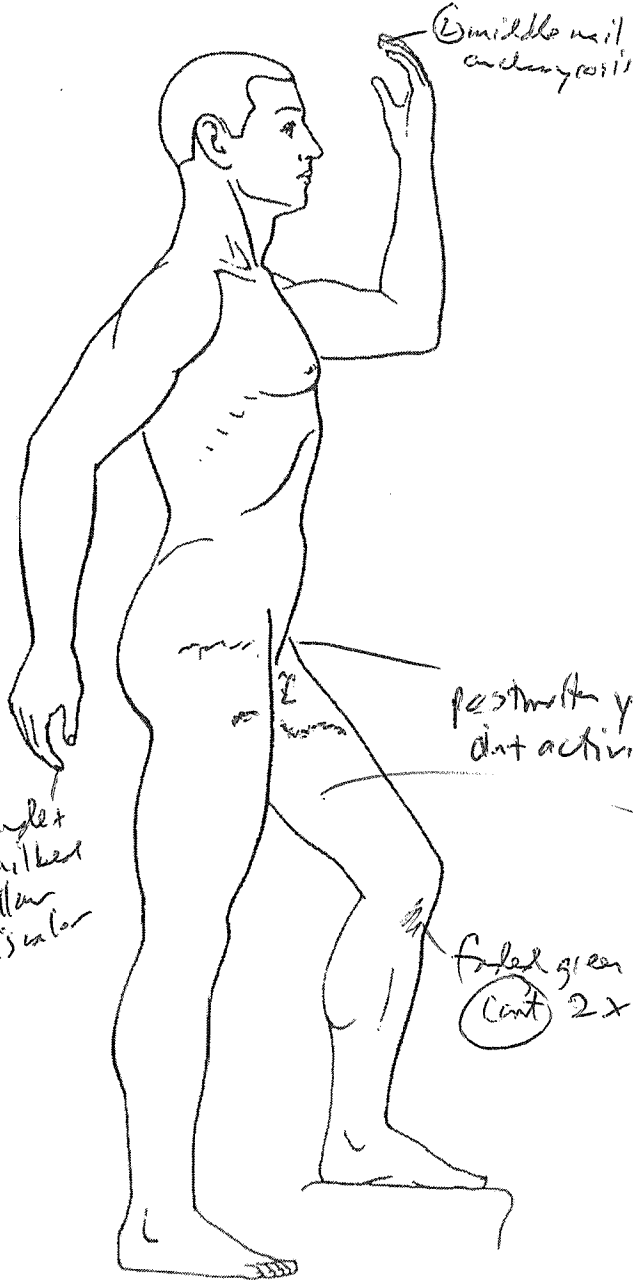
Date: 10/29/2023

Dr. Djabourian, Raffi
Medical Examiner

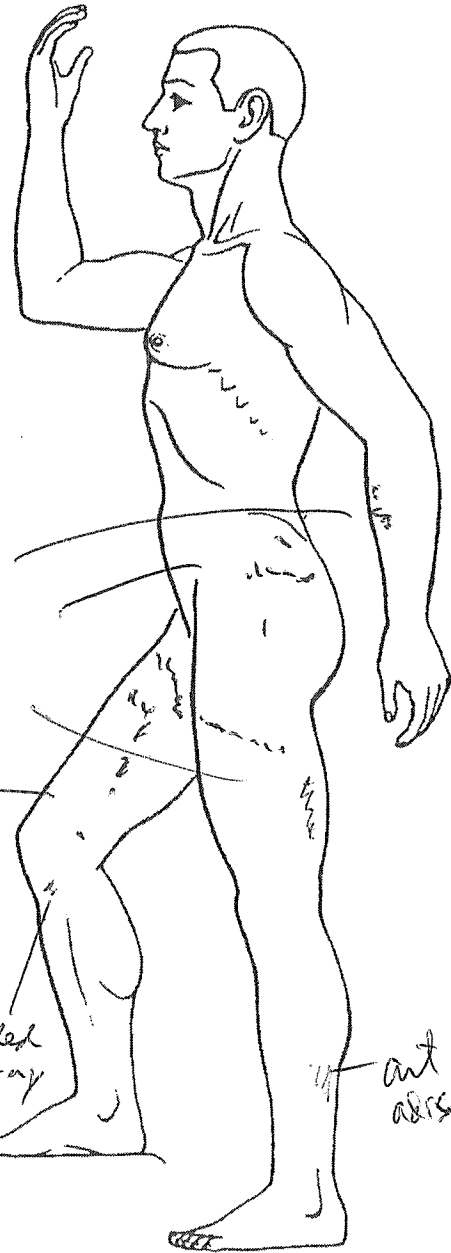
21

Decedent: PERRY, MATTHEW LANGFORD

Case Number: 2023-14789



Rt



Lt

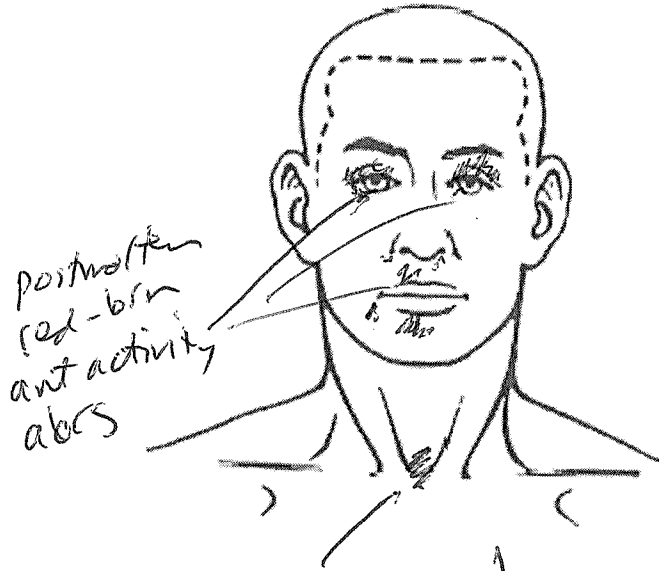
Date: 10/29/2023

Dr. Djabourian, Raffi
Medical Examiner

22

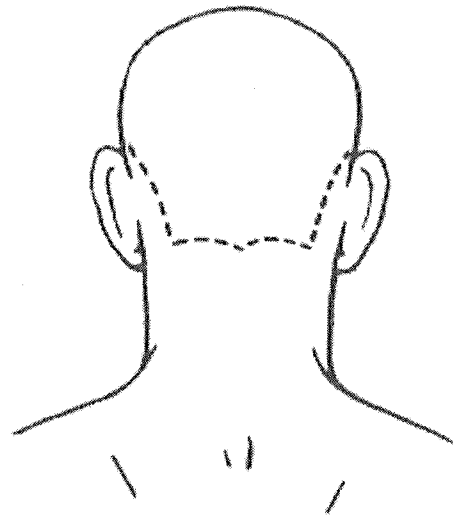
Decedent: PERRY, MATTHEW LANGFORD

Case Number: 2023-14789

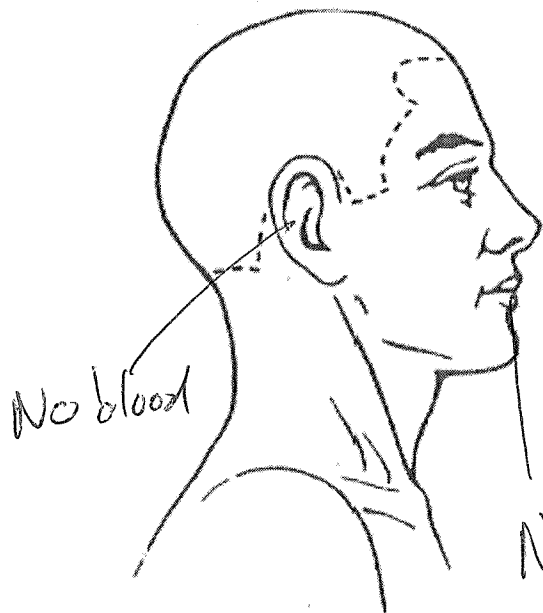


postmortem
red-brn
ant activity
abcs

3" scar infraoral

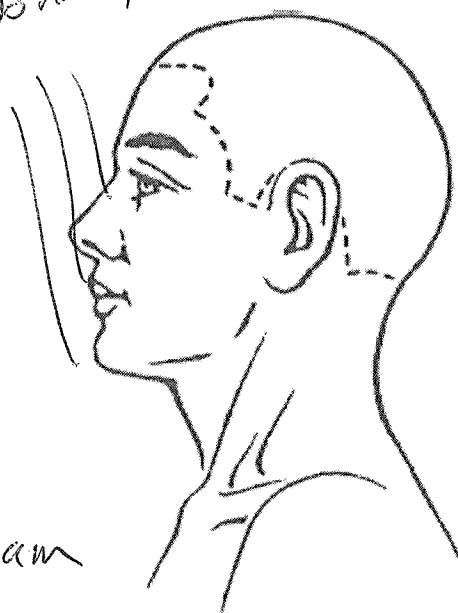


No nasal, mandib or maxillary frs



No blood

No foam



Date: 10/29/2023

Dr. Djabourian, Raffi
Medical Examiner

16

Decedent: PERRY, MATTHEW LANGFORD

Case Number: 2023-14789

EXTERNAL EXAM

Sex M
Race C
Age 54
Height 70
Weight 260 216 PD 12/13/23
Hair Seeding
Eyes
Sclera
Teeth
Mouth
Tongue
Nose
Chest
Breasts
Abdomen
Scar
Genitals
Edema
Skin
Decubitus



HEART Wt. 465
Pericardium 155 RV 0.5
Hypertrophy mild Septum 1.5
Dilation mild LV 1.5
Muscle TV/PV/MV/AV: 12.2/8/10.6/8
Valves e veg
Coronaries prox LAD to mid: 50/65/75%
AORTA mod abd
VESSELS epe
LUNGS Wt. C/R < 25

R 700
L 690
Adhesions sparse fibrous
Fluid 50SS
Atelectasis H-type inflated mildly,
Oedema mild to
Congestion
Consolidation
Bronchi marked anthracosis
Nodes traumatic & trauma

PHARYNX
TRACHEA
THYROID
THYMUS
LARYNX
HYOID
ABDOMINAL WALL FAT 1 3/4"



& = not present

PERITONEUM

Fluid
Adhesions Ribs

LIVER Wt. 2020
Capsule
Lobules "nutmeg" chronic congestive
Fibros
GB hobnail-grn
Calculus
Bile ducts

SPLEEN Wt. 340 ↑
Color
Consistency
Capsule
Malpignment

PANCREAS
ADRENALS
KIDNEYS Wt.

R 185
L 200
Capsule
Cortex Nephrosclerosis/
Vessels niting
Pelvis
Ureters
Bladder hazy yellow 15cc

GENITALIA
Prostate
Testes focal lesions
Uterus
Tubes
Ovaries

OESOPHAGUS
STOMACH contents
DUOD. & SM. INT. adhesions chronic
APPENDIX Not identified

LARGE INT.
ABDOM. NODES
SKELETON
Spine mild osteophytes & trauma
Marrow
Rib Cage
Long bones
Pelvis



SCALP
CALVARIUM
BRAIN Wt. 1450
Dura
Fluid
Ventricles
Vessels
Middle ears
Other
PITUITARY



SPINAL CORD

ND

TOXICOLOGY SPECIMENS

See Moon

SECTIONS FOR HISTOPATHOLOGY

St x 2
Cassettes 1-3 lungs w K/L

MICROBIOLOGY

NP → PIT

DIAGRAMS 20, 21, 22

X-RAYS CT trauma

OTHER PROCEDURES

Photo face, scalp, LAD (coronary)

GROSS IMPRESSIONS

See typed report

Date: 10/29/2023

Dr. Djabourian, Raffi
Medical Examiner

14I performed a microscopic examination on →
11/14/2023

2023-14789

at THE DEPARTMENT OF MEDICAL EXAMINER

Perry, Matthew Langford

Los Angeles, California

Microscopic description

Heart: There is no significant interstitial myocardial fibrosis. There is mild sparsely scattered myocyte nucleus hypertrophy. No acute inflammatory infiltrates are seen. There is no hemorrhage, necrosis, or significant epicardial or endocardial lesions.


Lungs: A few bronchioles show focal increase chronic inflammatory cell infiltrates in the walls with peribronchial lymphoid aggregates. No obvious asthmatic changes are noted. Alveoli show marked expansion in several areas with many areas showing disruption and destruction of the normal alveolar architecture, with bullous formation. However, there are no acute inflammatory exudates in the alveolar spaces. Anthracosis and finely pigmented alveolar macrophages are present in several interstitial and perivascular regions. A few scattered foreign body giant cell granulomas are noted with vegetable type material, focally showing calcification. Vascular congestion is mild.

Liver: Moderately severe centrilobular congestion and macrovesicular steatosis is present. No significant necrosis or hemorrhage is noted. Chronic portal region chronic inflammatory cell aggregates are noted.


Kidneys: Sclerotic glomeruli and chronic interstitial inflammation is noted in several areas, with mild focal tubular atrophy. No acute inflammatory changes are noted.

Slide Key: 1-3/5 Lungs 4/5 Kidney, liver 5/5 Heart

Diagnosis: --Emphysema, lungs
--Remote foreign body granulomas, vegetable/plant material, lung
--Chronic hepatic congestion with steatosis, liver
--Mild to moderate nephrosclerosis, kidneys



Raffi S. Djabourian, M.D.
Senior Deputy Medical Examiner



Date:



Department of Medical Examiner, County of Los Angeles
FORENSIC SCIENCE LABORATORIES

1104 North Mission Road, Los Angeles, CA 90033



Laboratory Analysis Summary Report

Djabourian, Raffi M.D.

Deputy Medical Examiner
 1104 North Mission Road
 Los Angeles, CA 90033

PendingTox

Case Number: 2023-14789

Decedent: PERRY, MATTHEW LANGFORD

<u>SPECIMEN</u>	<u>SERVICE</u>	<u>DRUG</u>	<u>RESULT</u>	<u>ANALYST</u>
Alcohol Quantitation/Confirmation				
Blood, Heart				
	Alcohol-GC/FID-HS	Ethanol	Negative	C. Castellino
Drug Screen				
Blood, Heart				
	ELISA-Immunoassay	Benzodiazepines	PP	A. Martinez
	ELISA-Immunoassay	Cocaine and Metabolites	ND	A. Martinez
	ELISA-Immunoassay	Fentanyl	ND	A. Martinez
	ELISA-Immunoassay	Methamphetamine & MDMA	ND	A. Martinez
	ELISA-Immunoassay	Opiates: Codeine & Morphine	ND	A. Martinez
	ELISA-Immunoassay	Opiates: Hydrocodone & Hydromorphone	ND	A. Martinez
	ELISA-Immunoassay	Phencyclidine	ND	A. Martinez
Drug Screen/Confirmation				
Blood, Femoral				
	Bases-LC/MS/MS	Ketamine	3540 ng/mL	C. Castellino
	Bases-LC/MS/MS	Norketamine	Present	C. Castellino
Blood, Heart				
	Bases-GC/NPD &/or MS	Bupropion	ND	M. Liebl
	Bases-GC/NPD &/or MS	Bupropion Metabolites	ND	M. Liebl
	Bases-GC/NPD &/or MS	Ketamine	Present	M. Liebl
	Bases-GC/NPD &/or MS	Norketamine	Present	M. Liebl
	Bases-GC/NPD &/or MS	Quetiapine	* Inc.	M. Liebl
	Bases-GC/NPD &/or MS	Quetiapine Metabolite	Present	M. Liebl
	Bases-LC/MS/MS	Ketamine	3271 ng/mL	C. Castellino
	Bases-LC/MS/MS	Norketamine	Present	C. Castellino
	Benzos (Free)-LC/MS/MS	7-Aminoclonazepam	48 ng/mL	A. Kazaryan
	Benzos (Free)-LC/MS/MS	Clonazepam	ND	A. Kazaryan

Case Number: 2023-14789

Decedent: PERRY, MATTHEW LANGFORD

<u>SPECIMEN</u>	<u>SERVICE</u>	<u>DRUG</u>	<u>RESULT</u>	<u>ANALYST</u>
	Benzos (Free)-LC/MS/MS	Lorazepam	8.4 ng/mL	A. Kazaryan
	Outside Test	Buprenorphine	Done	NMS Labs, Inc.
	Outside Test	Lamotrigine	Done	NMS Labs, Inc.
	Outside Test	Vilazodone	Done	NMS Labs, Inc.
	Vols-GC/FID-HS &/or MS	Acetone	ND	C. Castellino
	Vols-GC/FID-HS &/or MS	Isopropanol	ND	C. Castellino
Stomach Contents				
	Bases-LC/MS/MS	Ketamine	1.1 mg	C. Castellino
	Bases-LC/MS/MS	Norketamine	Present	C. Castellino
Vitreous				
	iSTAT	Electrolytes and Glucose	Done	L. Gil de Montes

NOTE: *Inconclusive due to analytical difficulties.

Legend:		ND	Not Detected	SNS	Specimen Not Suitable
g	Grams	ng/g	Nanograms per Gram	TNP	Test Not Performed
g%	Gram Percent	ng/mL	Nanograms per Milliliter	ug	Micrograms
Inc.	Inconclusive	PP	Presumptive Positive	ug/g	Micrograms per Gram
mg	Milligrams	QNS	Quantity Not Sufficient	ug/mL	Micrograms per Milliliter

The alcohol analysis was performed in accordance to California Code of Regulations "Title 17" compliance by a qualified analyst in the Forensic Toxicology Laboratory, Forensic Laboratories Division, County of Los Angeles Department of Medical Examiner.

Enzyme-linked immunosorbant assay (ELISA) provides only a preliminary analytical result that is contingent upon a confirmatory test. A "presumptive positive" (PP) signifies a detection of a drug class and must be confirmed by additional testing for true identification and/or quantitation of specific drug(s) present in the specimen.

Per the Department's Evidence Retention Policy, the blood specimen(s) will be retained for one year (minimum) and all other specimens six months (minimum) from Postmortem Exam.

Final Review By: Sarah Buxton de Quintana
 Digitally signed by Sarah Buxton de Quintana
 Date: 2023.12.05 13:28:11
 Sarah Buxton de Quintana
 Supervising Criminalist I

The above results relate only to the items sampled and tested and have been technically and administratively reviewed and are the opinions and conclusions of the analysts noted. The final review has been certified by the noted Toxicologist to ensure that all standard operating procedures were followed as set by the Forensic Toxicology Laboratory, Forensic Sciences Laboratory Division, County of Los Angeles Department of Medical Examiner.



NMS Labs

CONFIDENTIAL

200 Welsh Road, Horsham, PA 19044-2208
Phone: (215) 657-4900 Fax: (215) 657-2972
e-mail: nms@nmslabs.com

Robert A. Middleberg, PhD, F-ABFT, DABCC-TC, Laboratory Director

Toxicology Report

Report Issued 11/13/2023 18:19

To: 10139
Los Angeles County Medical Examiner
1104 N. Mission Road

Los Angeles, CA 90033

Patient Name PERRY, MATTHEW
Patient ID 2023-14789
Chain NMSCP303655
DOB Not Given
Sex Not Given
Workorder 23429017

Page 1 of 3

Positive Findings:

Table with 4 columns: Analyte, Result, Units, Matrix Source. Rows include Buprenorphine - Free (8.0 ng/mL) and Norbuprenorphine - Free (17 ng/mL), both from Heart Blood.

See Detailed Findings section for additional information

Testing Requested:

Table with 2 columns: Test, Test Name. Lists tests 0801B, 2484B, and 4790B with their corresponding test names.

Specimens Received:

Table with 6 columns: ID, Tube/Container, Volume/Mass, Collection Date/Time, Matrix Source, Labeled As. Shows specimen 001 in a Gray Stopper Glass Tube.

All sample volumes/weights are approximations.
Specimens received on 11/03/2023.



Sarah Buxton de Quintana
Digitally signed by Sarah Buxton de Quintana
Date: 2023.11.13 16:21:19 -08'00'



CONFIDENTIAL

Workorder 23429017
Chain NMSCP303655
Patient ID 2023-14789

Page 2 of 3

Detailed Findings:

Table with 6 columns: Analysis and Comments, Result, Units, Rpt. Limit, Specimen Source, Analysis By. Rows include Buprenorphine - Free and Norbuprenorphine - Free.

Other than the above findings, examination of the specimen(s) submitted did not reveal any positive findings of toxicological significance by procedures outlined in the accompanying Analysis Summary.

Reference Comments:

1. Buprenorphine - Free (Buprenex®) - Heart Blood:

Buprenorphine is a Schedule III controlled synthetic opioid that has both analgesic and opioid antagonist effects. Clinically it is used for pain treatment and as a pharmacotherapy for opioid dependence. Because buprenorphine has mixed agonist-antagonist activity, there is a ceiling to the subjective and adverse effects of the drug. Buprenorphine is metabolized in the liver by N-dealkylation to norbuprenorphine and both buprenorphine and norbuprenorphine undergo glucuronide conjugation; the portion which is not conjugated is termed 'free'. Sublingual tablets are commonly prescribed as a combination of buprenorphine and naloxone to discourage intravenous administration. Typical doses are 12 to 16 mg buprenorphine per day, although higher doses can be prescribed. Maximum plasma buprenorphine concentrations in patients maintained on varying buprenorphine doses were:

- 2 mg/day: 0.3 +/- 0.1 ng/mL
16 mg/day: 6.3 +/- 0.9 ng/mL
32 mg/day: 13 +/- 4.2 ng/mL

Symptoms of overdose include confusion, dizziness, respiratory depression and lethargy. While buprenorphine is well tolerated, even at high doses, fatal interactions with benzodiazepines have been reported. In 20 fatalities where buprenorphine was detected, blood concentrations were 1.1-29 ng/mL (mean=8.4 ng/mL). Other drugs were present in 19 cases, 18 of which were positive for benzodiazepines, primarily nordiazepam. The blood to plasma ratio of buprenorphine is approximately 1.0-1.4.

2. Norbuprenorphine - Free (Buprenorphine Metabolite) - Heart Blood:

Buprenorphine (Suboxone, Subutex) is a semi-synthetic opiate with partial agonist and antagonist actions. Buprenorphine is only available in the United States in a formulation which also contains the opiate antagonist naloxone. Buprenorphine is metabolized in the liver by N-dealkylation to norbuprenorphine and both buprenorphine and norbuprenorphine undergo glucuronide conjugation. Maximum plasma norbuprenorphine concentrations in patients maintained on varying buprenorphine doses were:

- 2 mg/day: 0.7 +/- 0.2 ng/mL
16 mg/day: 5.4 +/- 1.3 ng/mL
32 mg/day: 14 +/- 2.9 ng/mL

In 20 fatalities where buprenorphine was detected, blood concentrations of norbuprenorphine were 0.2-13 ng/mL (mean=2.6 ng/mL). Other drugs were present in 19 cases, 18 of which were positive for benzodiazepines, primarily nordiazepam. The blood to plasma ratio for norbuprenorphine is not known.

Chain of custody documentation has been maintained for the analyses performed by NMS Labs.

Unless alternate arrangements are made by you, the remainder of the submitted specimens will be discarded six (6) weeks from the date of this report; and generated data will be discarded five (5) years from the date the analyses were performed.



CONFIDENTIAL

Workorder 23429017
Chain NMSCP303655
Patient ID 2023-14789

Page 3 of 3

Workorder 23429017 was electronically signed on 11/13/2023 16:19 by:

Ayako Chan-Hosokawa, M.S., D-ABFT-FT
Forensic Toxicologist

Analysis Summary and Reporting Limits:

All of the following tests were performed for this case. For each test, the compounds listed were included in the scope. The Reporting Limit listed for each compound represents the lowest concentration of the compound that will be reported as being positive. If the compound is listed as None Detected, it is not present above the Reporting Limit. Please refer to the Positive Findings section of the report for those compounds that were identified as being present.

Test 0801B - Buprenorphine and Metabolite - Free (Unconjugated), Blood - Heart Blood

-Analysis by High Performance Liquid Chromatography/ Tandem Mass Spectrometry (LC-MS/MS) for:

Analyte	Rpt. Limit	Analyte	Rpt. Limit
Buprenorphine - Free	0.50 ng/mL	Norbuprenorphine - Free	0.50 ng/mL

Test 2484B - Lamotrigine, Blood - Heart Blood

-Analysis by High Performance Liquid Chromatography/ Tandem Mass Spectrometry (LC-MS/MS) for:

Analyte	Rpt. Limit	Analyte	Rpt. Limit
Lamotrigine	0.20 mcg/mL		

Test 4790B - Vilazodone, Blood - Heart Blood

-Analysis by High Performance Liquid Chromatography/ Tandem Mass Spectrometry (LC-MS/MS) for:

Analyte	Rpt. Limit	Analyte	Rpt. Limit
Vilazodone	5.0 ng/mL		

Home
1104 N. Mission Road, Los Angeles, CA 90033
Phone: 323-343-0530
Fax: -

Patient Test Report

Patient ID: 2023.14789 **Test Time:** 11/08/2023 10:06 AM
Patient Name: - **Operator ID:** 6
Gender: - **Panel:** CHEM8+
Sex: - **Upload Time:** 11/08/2023 12:30 PM
DOB: - **Transfer Time:** -
Specimen Type: OTHR **LIS Status:** Not Sent
Device Model: i-STAT1
Device Serial No: 373835
Instrument Comment: -

Test	Flag	Result	Unit	Reference Range
Na		125	mmol/L	138 — 146
K	H	>9.0	mmol/L	3.5 — 4.900
Cl		105	mmol/L	98 — 109
BUN		16	mg/dL	8 — 26
Crea		0.7	mg/dL	0.600 — 1.299
Glu	L	<20	mg/dL	70 — 105

Total number of records: 1

Report Created By:

sdq

Signature:

Lauren Gil de
Montes

Digitally signed by Lauren Gil
de Montes
Date: 2023.11.09 07:02:04
-08'00'



COUNTY OF LOS ANGELES - DEPARTMENT OF PUBLIC HEALTH
 PUBLIC HEALTH LABORATORY - 12750 ERICKSON AVENUE, DOWNEY, CA 90242
 NICOLE M. GREEN, PhD, D(ABMM), DIRECTOR (562)658-1330

NAME: PERRY, MATTHEW L. LOC: L.A. COUNTY CORONERS OFFICE
 PATIENT ID# LACCO-202314789 DOB: 08/19/1969 AGE: 54Y SEX: M
 REQ'D BY: REFERRED, REFERRED

ACCT: LACCO202314789

COLLECTED: 10/29/2023 09:55 RECEIVED: 10/30/2023 09:40
 ACC. NO.: M25099 Order Comment:

TEST NAME	TEST RESULTS	REFERENCE RANGE
SARS CoV 2 NAAT	REQUEST CREDITED. DUPLICATE ORDER. THE RESPIRATORY PCR PANEL ALSO TESTS FOR SARSCOV2.	

TEST NAME	TEST RESULTS	REFERENCE RANGE
Multiplex Respiratory Panel PCR w/Reflex		

SPECIMEN DESCRIPTION	TEST RESULTS	REFERENCE RANGE
	NASOPHARYNGEAL SWAB	
	<i>Result date, time: 10/30/2023, 09:41</i>	
Adenovirus	NOT DETECTED	NDETEC
	<i>Result date, time: 10/30/2023, 13:23</i>	
Coronavirus 229E	NOT DETECTED	NDETEC
	<i>Result date, time: 10/30/2023, 13:23</i>	
Coronavirus HKU1	NOT DETECTED	NDETEC
	<i>Result date, time: 10/30/2023, 13:23</i>	
Coronavirus NL63	NOT DETECTED	NDETEC
	<i>Result date, time: 10/30/2023, 13:23</i>	
Coronavirus OC43	NOT DETECTED	NDETEC
	<i>Result date, time: 10/30/2023, 13:23</i>	
SARS CoV 2	NOT DETECTED	NDETEC
	<i>Result date, time: 10/30/2023, 13:23</i>	
Human Metapneumovirus	NOT DETECTED	NDETEC
	<i>Result date, time: 10/30/2023, 13:23</i>	
Human Rhinovirus/ Enterovirus	NOT DETECTED	NDETEC
	<i>Result date, time: 10/30/2023, 13:23</i>	
Influenza A	NOT DETECTED	NDETEC
	<i>Result date, time: 10/30/2023, 13:23</i>	

PERRY, MATTHEW L.
 CLIENT REPORT

CONTINUED
 ACCOUNT NO.: LACCO20231 PRINT DATE & TIME: 10/31/2023 07:52

COUNTY OF LOS ANGELES - DEPARTMENT OF PUBLIC HEALTH
 PUBLIC HEALTH LABORATORY - 12750 ERICKSON AVENUE, DOWNEY, CA 90242
 NICOLE M. GREEN, PhD, D(ABMM), DIRECTOR (562)658-1330

NAME: PERRY, MATTHEW L. LOC: L.A. COUNTY CORONERS OFFICE
 PATIENT ID# LACCO-202314789 DOB: 08/19/1969 AGE: 54Y SEX: M
 REQ'D BY: REFERRED, REFERRED

ACCT: LACCO202314789

COLLECTED: 10/29/2023 09:55 RECEIVED: 10/30/2023 09:40
 ACC. NO.: M25099 Order Comment:

TEST NAME	TEST RESULTS	REFERENCE RANGE
Multiplex Respiratory Panel	PCR w/Reflex (CONTINUED) Result date, time: 10/30/2023, 13:23	
Influenza A H1	* NOT APPLICABLE Result date, time: 10/30/2023, 13:23	NDETEC
Influenza A H3	* NOT APPLICABLE Result date, time: 10/30/2023, 13:23	NDETEC
Influenza A H1 2009	* NOT APPLICABLE Result date, time: 10/30/2023, 13:23	NDETEC
Influenza B	NOT DETECTED Result date, time: 10/30/2023, 13:23	NDETEC
Parainfluenza Virus 1	NOT DETECTED Result date, time: 10/30/2023, 13:23	NDETEC
Parainfluenza Virus 2	NOT DETECTED Result date, time: 10/30/2023, 13:23	NDETEC
Parainfluenza Virus 3	NOT DETECTED Result date, time: 10/30/2023, 13:23	NDETEC
Parainfluenza Virus 4	NOT DETECTED Result date, time: 10/30/2023, 13:23	NDETEC
Respiratory Syncytial Virus	NOT DETECTED Result date, time: 10/30/2023, 13:23	NDETEC
Bordetella parapertussis	NOT DETECTED Result date, time: 10/30/2023, 13:23	NDETEC
Bordetella pertussis	NOT DETECTED Result date, time: 10/30/2023, 13:23	NDETEC

PERRY, MATTHEW L.
 CLIENT REPORT

CONTINUED
 ACCOUNT NO.: LACCO20231 PRINT DATE & TIME: 10/31/2023 07:52

PAGE 2

COUNTY OF LOS ANGELES - DEPARTMENT OF PUBLIC HEALTH
 PUBLIC HEALTH LABORATORY - 12750 ERICKSON AVENUE, DOWNEY, CA 90242
 NICOLE M. GREEN, PhD, D(ABMM), DIRECTOR (562)658-1330

NAME: PERRY, MATTHEW L. LOC: L.A. COUNTY CORONERS OFFICE
 PATIENT ID# LACCO-202314789 DOB: 08/19/1969 AGE: 54Y SEX: M
 REQ'D BY: REFERRED, REFERRED

ACCT: LACCO202314789

COLLECTED: 10/29/2023 09:55 RECEIVED: 10/30/2023 09:40
 ACC. NO.: M25099 Order Comment:

TEST NAME	TEST RESULTS	REFERENCE RANGE
Multiplex Respiratory Panel PCR w/Reflex	(CONTINUED)	
	Result date, time: 10/30/2023, 13:23	
Chlamydomphila pneumoniae	NOT DETECTED	NDETEC
	Result date, time: 10/30/2023, 13:23	
Mycoplasma pneumoniae	NOT DETECTED	NDETEC
	Result date, time: 10/30/2023, 13:23	

Additional Comments

The FilmArray Respiratory (RP) panel is a qualitative, multiplex, nucleic acid-based test capable of the simultaneous detection and identification of multiple viruses and bacteria directly from nasopharyngeal samples obtained from individuals with signs and/or symptoms of respiratory infection. This test is intended as an aid in the diagnosis of specific agents of respiratory illness, and results are meant to be used in conjunction with other clinical, laboratory, and epidemiologic data. Positive results do not rule out co-infection with other organisms not included on the panel, and the agent detected may not be the definitive cause of disease.

Rarely, multiple analytes may be detected. If four or more distinct organisms are detected in a specimen, an additional sample may be requested to confirm polymicrobial result. This test does not differentiate Rhinovirus and Enterovirus. Additional testing is required for Influenza subtyping. This test is not intended to be used to monitor treatment and results do not necessarily detect live organisms. For equivocal results, please submit additional specimen.

Result date, time: 10/30/2023, 13:23

PERRY, MATTHEW L.
 CLIENT REPORT

END OF REPORT
 ACCOUNT NO.: LACCO20231 PRINT DATE & TIME: 10/31/2023

PAGE 3
 07:52



"Enriching Lives"

COUNTY OF LOS ANGELES DEPARTMENT OF MEDICAL EXAMINER

1104 N. MISSION RD, LOS ANGELES, CALIFORNIA 90033

Case Number: 2023-14789 - Decedent's Name: PERRY, MATTHEW LANGFORD



Odey C. Ukpo, M.D., M.S.
Interim Chief Medical Examiner

COUNTY OF LOS ANGELES		INVESTIGATIVE SUMMARY REPORT				DEPARTMENT OF MEDICAL EXAMINER					
1	APPARENT MODE	Accident				CASE NO 2023-14789					
	SPECIAL CIRCUMSTANCES	Celebrity / Media Interest				CRYPT SC-1					
LAST, FIRST MIDDLE PERRY, MATTHEW LANGFORD					AKA		#				
ADDRESS 18038 Blue Sail Dr, Pacific Palisades, CA 90272					CITY		STATE		ZIP		
SEX	RACE APPEARS	DOB	AGE	HGT	WGT	EYES	HAIR	TEETH	FACIAL HAIR	ID VIEW	CONDITION
Male	White/Caucasian	8/19/1969	54 y	70 in	216 lb	Blue	Blond	Natural	Yes	Yes	FAIR
MARK TYPE		MARK LOCATION				MARK DESCRIPTION					
Amputation		Right Middle Finger				Distal end					
Scar		Right Abdomen				horizontal scar tissue					
NOK		ADDRESS				CITY		STATE		ZIP	
RELATIONSHIP Power of Attorney		PHONE				PENDING BY		DATE 10/28/2023		TIME	
SSN		DL ID				STATE CALIFORNIA					
ID METHOD CA DL											
L.A. #		MAIN #		CIL #		FBI #		MILITARY #		POB	
IDENTIFIED BY NAME(PRINT)				RELATIONSHIP		PHONE		DATE 10/29/2023		TIME	
PLACE OF DEATH/PLACE FOUND Residence				ADDRESS OR LOCATION 18038 Blue Sail Dr, Pacific Palisades, CA 90272				CITY		ZIP	
PLACE OF INJURY Pool of Residence		AT WORK No	DATE 10/28/2023	TIME	LOCATION OR ADDRESS 18038 Blue Sail Dr, Pacific Palisades, CA 90272,				ZIP		
DOD 10/28/2023		TIME 16:17:00		FOUND OR PRONOUNCED BY Boswell #32074, LAFD RA/Eng23							
OTHER AGENCY INV OFFICER LAPD ROBBERY HOMICIDE DIVISION				PHONE		REPORT No 231000002691					
TRANSPORTED BY Scott, Alfred				DATE 10/29/2023		TIME 01:35:00					
FINGERPRINTS? Yes		CLOTHING Yes			PA RPT No			MORTUARY			
MED EV Yes		INVEST PHOTOS# 136			SEAL TYPE NOT SEALED			HOSPRPT No			
PHYS EV No					PROPERTY? Yes			HOSP CHART No			
SUICIDE NOTE No								PF NO			



"Enriching Lives"

COUNTY OF LOS ANGELES DEPARTMENT OF MEDICAL EXAMINER

1104 N. MISSION RD, LOS ANGELES, CALIFORNIA 90033

Case Number: **2023-14789** - Decedent's Name: **PERRY, MATTHEW LANGFORD**



Odey C. Ukpo, M.D., M.S.
Interim Chief Medical Examiner

SYNOPSIS

Detectives are requesting a TWO-HOUR exam notice, and would like the exam to happen on 10/29 due to being in court for homicide investigations on Monday On 10/28/2023 at 1337 hours, the decedent was last known alive by his personal live-in assistant, who left the residence to run errands. At 1600 hours, the assistant returned home, and found the decedent floating face down in the heated end of the pool. The assistant jumped into the pool, moved the decedent into a sitting position on the steps, and called 911. Paramedics responded, pulled the decedent out of the pool onto the grass, and pronounced on scene. Decedent had a history of chronic obstructive pulmonary disease, emphysema, diabetes, and depression. Decedent had a prior history of drug abuse (clean 19 months), history of cigarette smoking two packs a day (recently quit), and his last ketamine treatment was a week and a half ago. There was no foam present in the mouth or nares. The decedent was warm to touch, had lividity to the back (blanched light pressure), and rigor mortis was a 4. Minor contusions and abrasions throughout. No obvious external traumatic injuries noted. Multiple prescriptions and loose pills collected from scene. No alcohol, illicit drugs, or drug paraphernalia found. No foul play suspected.



"Enriching Lives"

COUNTY OF LOS ANGELES DEPARTMENT OF MEDICAL EXAMINER

1104 N. MISSION RD, LOS ANGELES, CALIFORNIA 90033

Case Number: **2023-14789** - Decedent's Name: **PERRY, MATTHEW LANGFORD**



Odey C. Ukpo, M.D., M.S.
Interim Chief Medical Examiner

COUNTY OF LOS ANGELES

Investigator's Narrative

DEPARTMENT OF CORONER

Information Sources:

1. Detective Stearns #31611 and Detective Sean #36979. LAPD Robbery-Homicide Division Homicide Special Section, 100 W. 1st Street, Los Angeles, CA, 90012.
2. [REDACTED] (executor of will). [REDACTED]
3. On Scene Investigation.

Investigation:

On Saturday, 10/28/2023 at 1701 hours, Officer Dominguez from Los Angeles Police Department West LA reported this apparent accident death to Cleric Rushad Trapp, reporting desk, at the Los Angeles County Department of Medical Examiner. It was reported that the decedent was found floating in the "jacuzzi" by his assistant. Paramedics pronounced the decedent on scene. Officers observed no evidence of illicit drugs, drug paraphernalia, foul play, or trauma. It was later reported that Detectives were responding to the scene, and this was a first call. I was assigned this field call by Lieutenant Ricardo Lopez on Saturday, October 28, 2023 at approximately 2131 hours. Lieutenant Rudy Molano also responding to the scene.

Location:

Location of Death: 18038 Blue Sail Dr, Pacific Palisades, CA 90272 Location of Injury: 18038 Blue Sail Dr, Pacific Palisades, CA 90272



"Enriching Lives"

COUNTY OF LOS ANGELES DEPARTMENT OF MEDICAL EXAMINER

1104 N. MISSION RD, LOS ANGELES, CALIFORNIA 90033

Case Number: 2023-14789 - Decedent's Name: PERRY, MATTHEW LANGFORD



Odey C. Ukpo, M.D., M.S.
Interim Chief Medical Examiner

Informant/Witness Statements:

According to Detectives at the scene, all information provided was preliminary; the LAPD Robbery-Homicide investigation will be ongoing.

On 10/28/2023 around 1100 hours, the decedent had played pickleball. At 1337 hours, the decedent was last known alive by his personal live-in assistant, who left the residence to run errands. At 1600 hours, the assistant returned home, and found the decedent floating face down in the heated end of the pool. The assistant jumped into the pool, moved the decedent into a sitting position on the steps, and called 911. Los Angeles Fire Department Rescue Ambulance and Engine #23 responded, pulled the decedent out of the pool onto the grass, and Boswell #32074 pronounced at 1617 hours. Door notices are consistent with the times the assistant provided of leaving and arriving back at the residence with the residence alarms not being triggered any other times. The password protected drive for the video of the backyard was pulled; however, they believe that it might not have been activated at the time of the incident. The assistant did not report any recent illnesses, complaints, drinking, or drug abuse. The decedent's assistant provided them a list of all medications, many had been stopped; however, decedent was currently taking Subutex twice a day. The assistant was responsible for administering the medication. The decedent was seeing a psychiatrist: Dr Yaghamie [REDACTED] and was prescribed antidepressants. The decedent's current primary care physician was an anesthesiologist Dr Atao [REDACTED]. They have found no apparent illicit drugs, drug paraphernalia, or alcohol; only nicotine vape products. Per the assistant, the decedent was currently smoking two packs of cigarettes a day. Decedent had a medical history of chronic obstructive pulmonary disease and emphysema. The decedent had a contact in his right eye from a surgery.

I interviewed [REDACTED] via telephone; in essence she revealed the following information: She last spoke to the decedent a few days ago, and he seemed fine and was in "good spirits". The decedent had a medical history of emphysema, diabetes, depression, and anxiety. The decedent had a prior history of depression, but had told her he would "never kill himself". To her knowledge, the decedent had never made suicidal statements, and had no known prior suicide attempts. Decedent was having Ketamine treatments: his last doctor was treating him more frequently, and he was having treatments every other day; but his new doctor of 6 months stated that since he was in a good mood, his depression was fine, and he did not need more treatments. His most recent known treatment was a week and a half ago. The decedent had been sober for 19 months with no known relapse; was taking 30 mg of Subutex, and was hoping to be weaned down. To her knowledge, the decedent had just stopped smoking two weeks ago. The decedent was prescribed Tamoxifen to lose weight, and was also getting testosterone shots, which she believes were causing him to be "angry and mean" for the last couple weeks.

During my scene investigation, no alcohol, illicit drugs, or drug paraphernalia were found. In the assistant's bedroom, there were multiple open, empty, half-filled medication bottles prescribed to the decedent as well as over-the-counter medications, vitamins, digestive aids, and dishes filled with multiple various loose pills, tablets, caplets, candy, and breath mints. In the living room, there were multiple nicotine vaping products, and an inhaler. In the refrigerator, there was Tirzepatide injectables and nicotine lollypops. There were used ashtrays throughout the residence. In the decedent's bathroom, there were various prescribed ointments, digestive aids, and oral rinses.

Scene Description:

I left the Forensic Science Center at 2156 hours, and I arrived at the scene at 2232 hours. The scene was located in the backyard of a residence on the south side of Blue Sail Drive, west of S Surfview Drive. There was a gravel path on the east side of the property to the backyard of the residence, which contained a pool with covered patio sections to the north (along the residence), and along the west side of the property. There were steps on the west side of the pool into the pool area with a raised divider between the pool, and the heated section at the east end of the pool. The heated section had a step around it. There was grass between the pool, and the covered patio sections near the residence. North of the heated end of the pool, the decedent was located lying supine in the grass area with his feet towards the pool (south), and his head towards the residence (north). I left the scene at 0105 hours, and arrived back at the Forensic Science Center at 0205 hours.



"Enriching Lives"

COUNTY OF LOS ANGELES DEPARTMENT OF MEDICAL EXAMINER

1104 N. MISSION RD, LOS ANGELES, CALIFORNIA 90033

Case Number: 2023-14789 - Decedent's Name: PERRY, MATTHEW LANGFORD



Odey C. Ukpo, M.D., M.S.
Interim Chief Medical Examiner

Body Examination:

On 10/29/2023 at 0135 hours, the decedent was transported from 18038 Blue Sail Drive, and was brought to the Forensic Science Center. The decedent was then processed in the facility at 0205 hours on 10/29/2023 by Forensic Attendant Alfred Scott. At the time of processing, the decedent was recorded with a height of 70 inches and a weight of 216 pounds. The decedent is an adult Caucasian male who appears to be the reported 54 years of age with short brown hair, blue eyes, beard and mustache, and natural teeth.

The decedent was clothed lying supine on the ground.

The decedent was wearing black underwear.

Disposable electrocardiogram patches were in place.

Insects were present. There was skin slip, and an apparent fluid filled blister on the back. There was a hard discoloration to the posterior right knee. There was yellow discoloration to the fingernail on the right pointer finger.

There were minor contusions and abrasions throughout.

The decedent had horizontal scar tissue on his right abdomen, and irregular scar tissue on the midline shoulder girdle. The distal end of the right middle finger was amputated (healed).

The decedent felt warm to the touch. There was lividity showing in the back (with Tardieu spots), that blanched to light pressure. Rigor mortis was a 4.

Identification:

The decedent's California Driver License was released to me by Detectives on scene. I confirmed this with California Department of Motor Vehicles Identification [REDACTED] Perry, Matthew Langford.

Next of Kin Notification:

Per the decedent's stepmother [REDACTED] the decedent was never married, had no children, his biological parents are alive, and is believed to have an advanced health care directive. At the time of this report, the decedent's advanced health care directive has not been reviewed or confirmed.

Tissue Donation:

Tissue donation was not discussed with the family because they were distraught.

Autopsy Notification:

LAPD Robbery-Homicide Detective Stearns requests a TWO-Hour exam notice. Please see case notes for confidential contact information.

Evidence:

Lamotrigine collected on 2023-10-28, at approximately 23:45:00 hours - Investigator - Hertzog, Jennifer

bUPROPION HCL collected on 2023-10-28, at approximately 23:45:00 hours - Investigator - Hertzog, Jennifer

collected on 2023-10-28, at approximately 23:45:00 hours - Investigator - Hertzog, Jennifer

Quetiapine Fumarate collected on 2023-10-28, at approximately 23:45:00 hours - Investigator - Hertzog, Jennifer

propecia collected on 2023-10-28, at approximately 23:45:00 hours - Investigator - Hertzog, Jennifer

metformin hcl collected on 2023-10-28, at approximately 23:45:00 hours - Investigator - Hertzog, Jennifer

pantoprazole sod dr collected on 2023-10-28, at approximately 23:45:00 hours - Investigator - Hertzog, Jennifer

mounjaro collected on 2023-10-28, at approximately 23:45:00 hours - Investigator - Hertzog, Jennifer

xyosted collected on 2023-10-28, at approximately 23:45:00 hours - Investigator - Hertzog, Jennifer

nicotine lollypop collected on 2023-10-28, at approximately 23:45:00 hours - Investigator - Hertzog, Jennifer

vilazodone hcl collected on 2023-10-28, at approximately 23:45:00 hours - Investigator - Hertzog, Jennifer

rosuvastatin calcium collected on 2023-10-28, at approximately 23:45:00 hours - Investigator - Hertzog, Jennifer

collected on 2023-10-28, at approximately 23:45:00 hours - Investigator - Hertzog, Jennifer



"Enriching Lives"

COUNTY OF LOS ANGELES DEPARTMENT OF MEDICAL EXAMINER

1104 N. MISSION RD, LOS ANGELES, CALIFORNIA 90033

Case Number: **2023-14789** - Decedent's Name: **PERRY, MATTHEW LANGFORD**



Odey C. Ukpo, M.D., M.S.
Interim Chief Medical Examiner

buprenorphine collected on 2023-10-28, at approximately 23:45:00 hours - Investigator - Hertzog, Jennifer
quviviq collected on 2023-10-28, at approximately 23:45:00 hours - Investigator - Hertzog, Jennifer
cyanocobalamin collected on 2023-10-28, at approximately 23:45:00 hours - Investigator - Hertzog, Jennifer
sildenafil collected on 2023-10-28, at approximately 23:45:00 hours - Investigator - Hertzog, Jennifer
tadalafil collected on 2023-10-28, at approximately 23:45:00 hours - Investigator - Hertzog, Jennifer
vilazodone hcl collected on 2023-10-28, at approximately 23:45:00 hours - Investigator - Hertzog, Jennifer
buprenorphine collected on 2023-10-28, at approximately 23:45:00 hours - Investigator - Hertzog, Jennifer
minoxidil-fluocinolone acetone: tretinoin collected on 2023-10-28, at approximately 23:45:00 hours - Investigator - Hertzog, Jennifer
collected on 2023-10-28, at approximately 23:45:00 hours - Investigator - Hertzog, Jennifer

Jennifer Hertzog

Earl Aimee

Investigator: Hertzog, Jennifer
Inv. Report Date/Time: 10/29/2023 at 07:22:00

Reviewed By: Earl, Aimee
Reviewed Date/Time: 10/29/2023 at 10:54:00